

MOD restoration on first Molar

Procedure/Study by

Dr. Giuseppe Chiodera, Brescia – Italy

myQuickmat Classico kit



Dr. Chiodera graduated in Dentistry at the University of Brescia .
In year 2004 he won a scholarship at Kings College University of London.

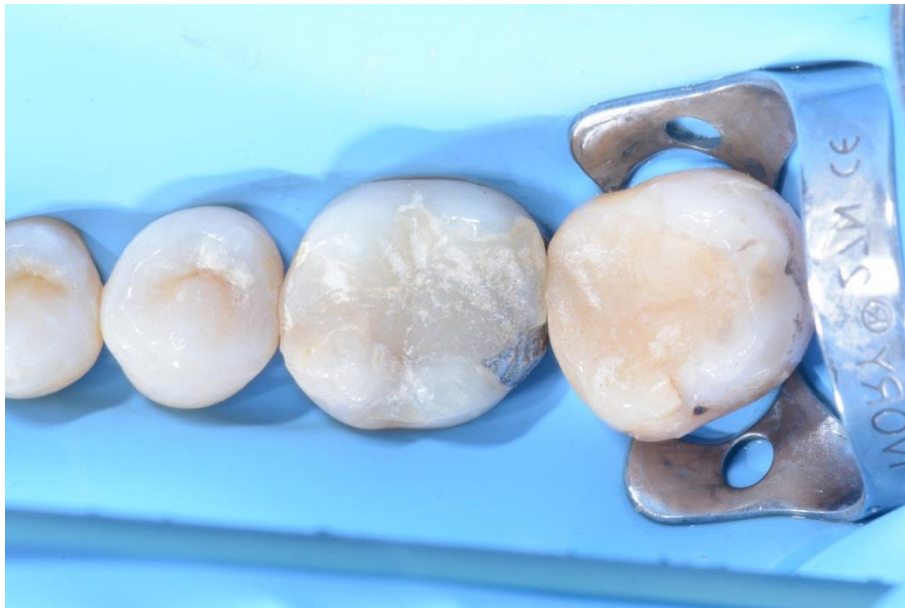Member of Style Italiano, Dr. Chiodera is having a private practice in Italy since 2006 and his practice is mainly dedicated to conservative dentistry and endodontics .

Dr. Chiodera is also very active as author of National and International Journal articles, as well as Lecturer in many Universities.

Case Report

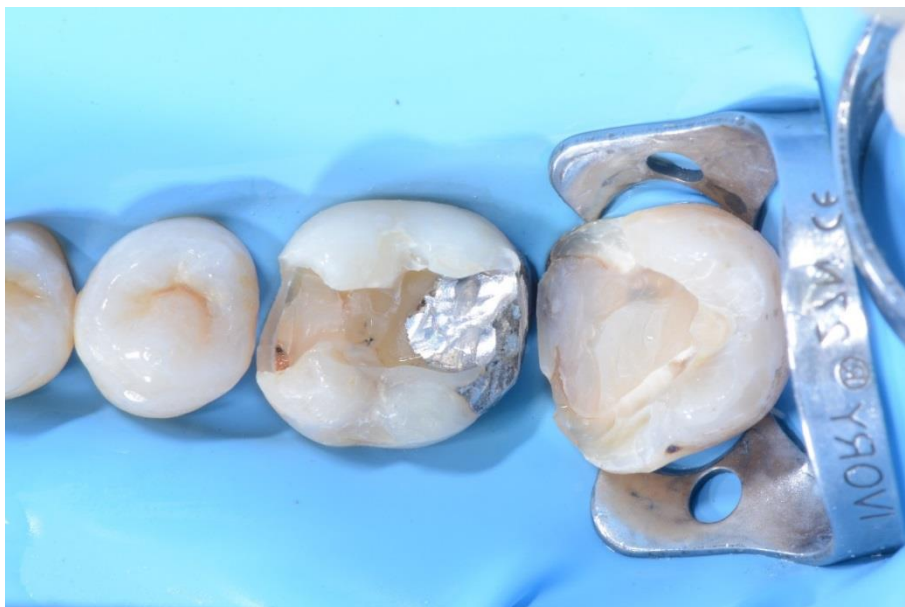The patient presented a previous composite restoration over an old amalgam filling that should be replaced on molar 46 and a carious lesion on molar 47 mesial.

The following case shows the step-by-step direct composite restoration of the first molar using the Polydentia myQuickmat Classico kit.



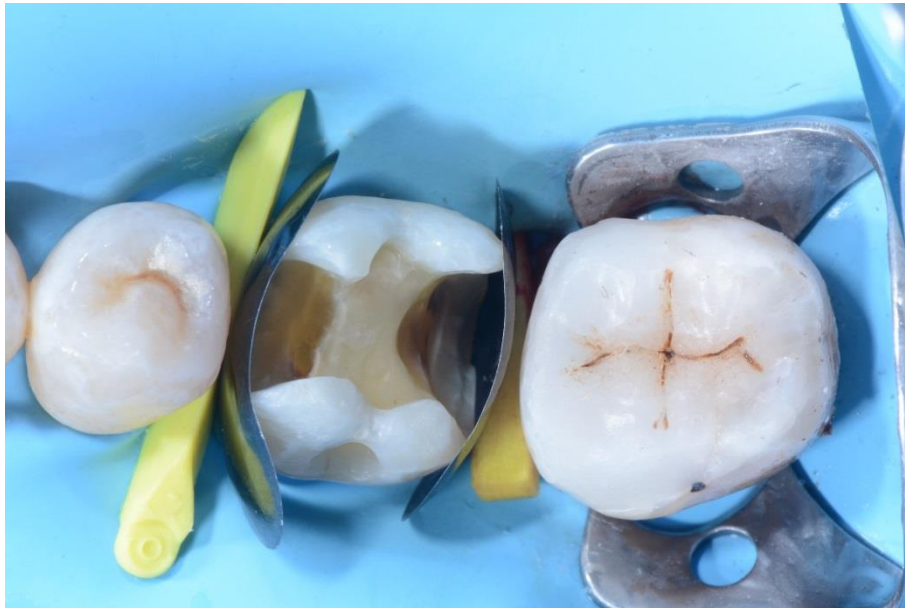01

Pre-operative view of 46 and 47 molars showing an old composite restoration over amalgam which should be replaced on #46 and a carious lesion on 47.



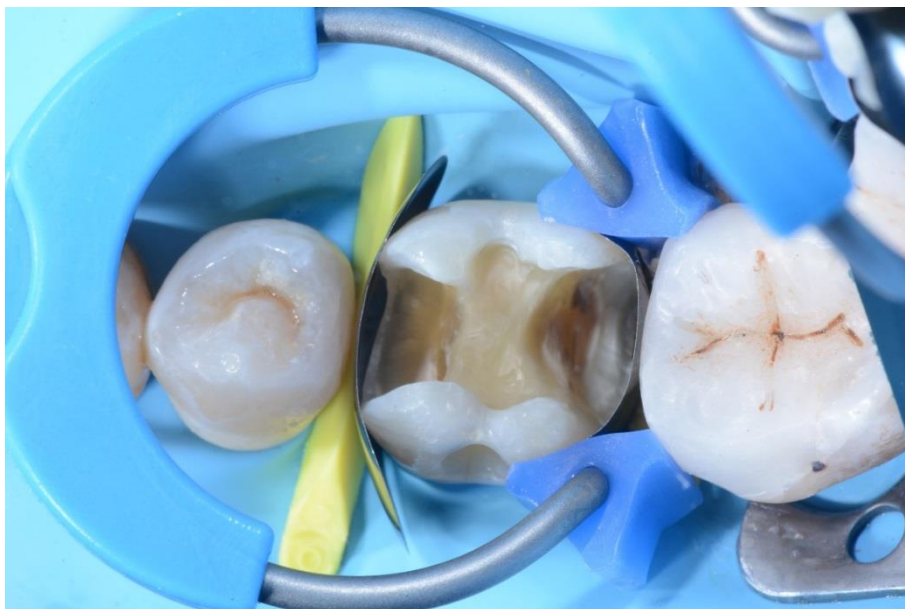02

Partially prepared cavities; before proceeding with the MOD restoration of first molar, the class II on 47 was restored first.



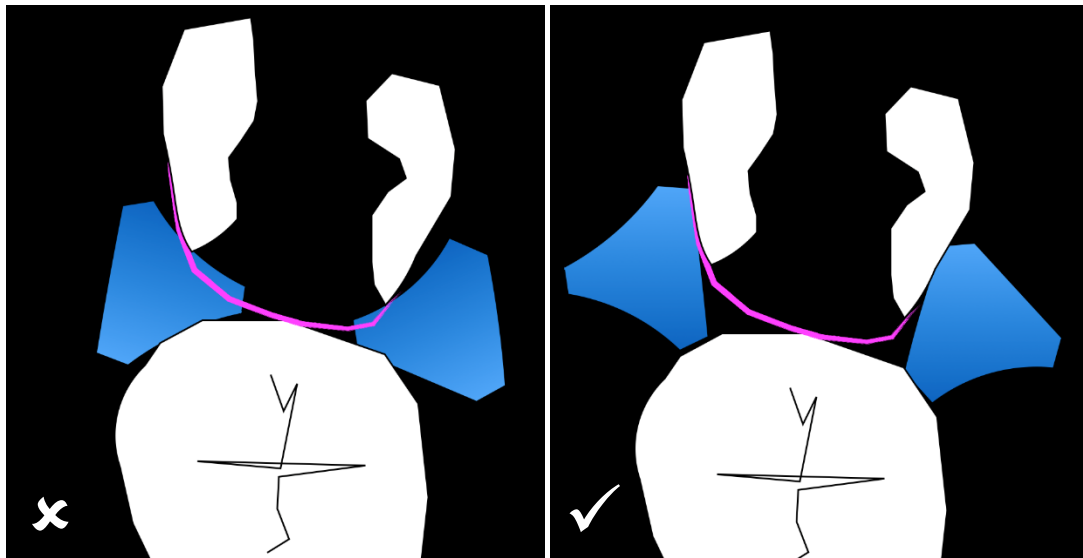
03

Occlusal view of the first molar equipped with LumiContrast sectional matrices and wedges.



04

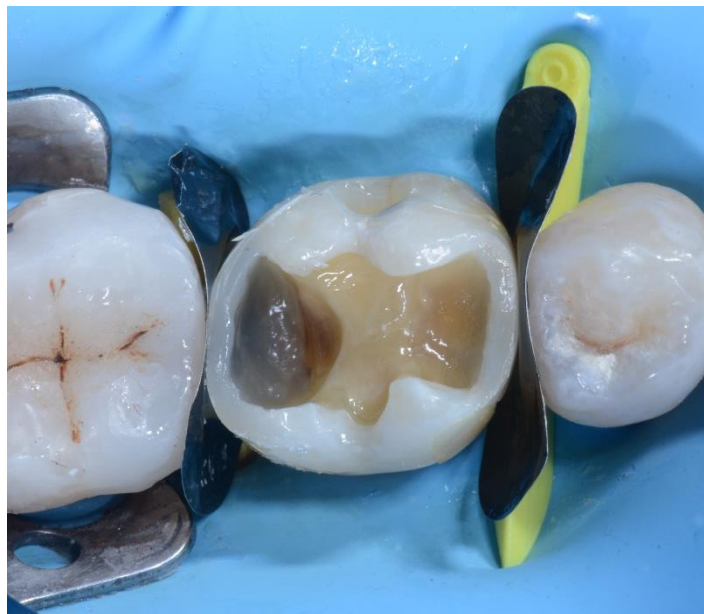The MOD cavity on 46 molar equipped with the myRing Classico for the distal interproximal wall restoration. Delta Tubes have been used to improve the adaptation of the LumiContrast matrix to the lingual and buccal walls.



05 Incorrect Delta Tubes orientation

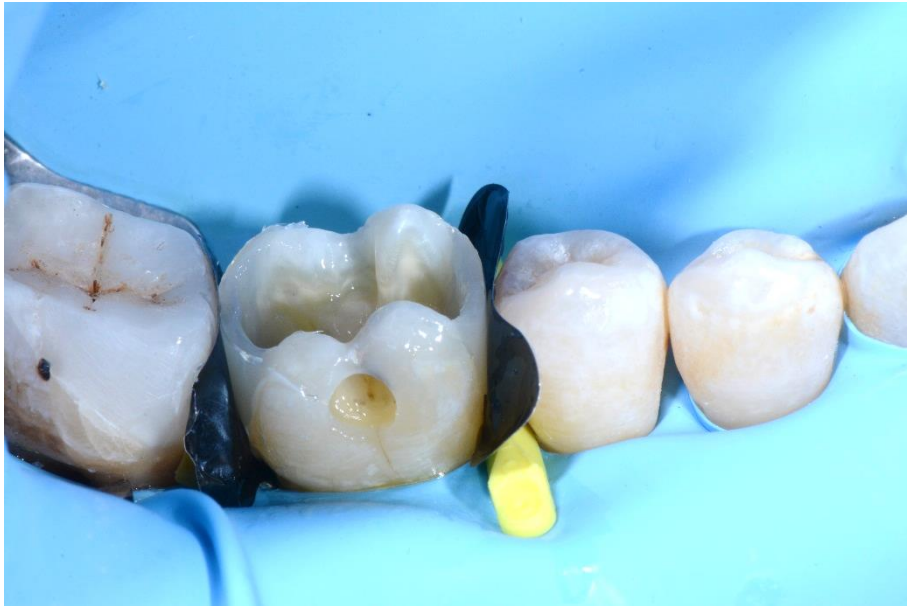Correct Delta Tubes Orientation

This illustration shows the importance of the correct orientation of the Delta Tubes. A correct orientation of the Delta Tubes ensures optimal adaptation of the matrix to the lingual and buccal walls, without damaging or collapsing the matrix band into the cavity.



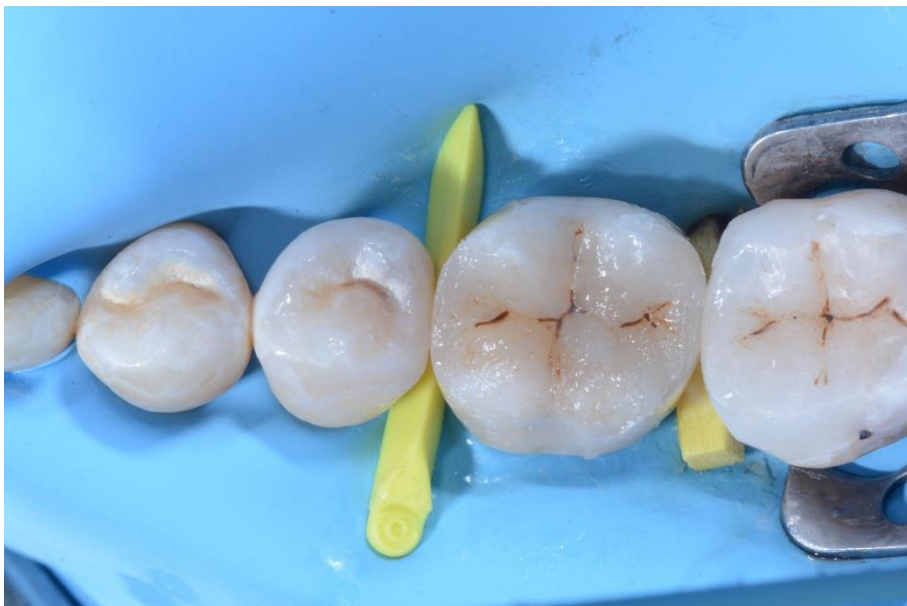06

46 after restoration of the distal and mesial interproximal walls, removal of myRing Classico and detachment of the LumiContrast sectional matrices



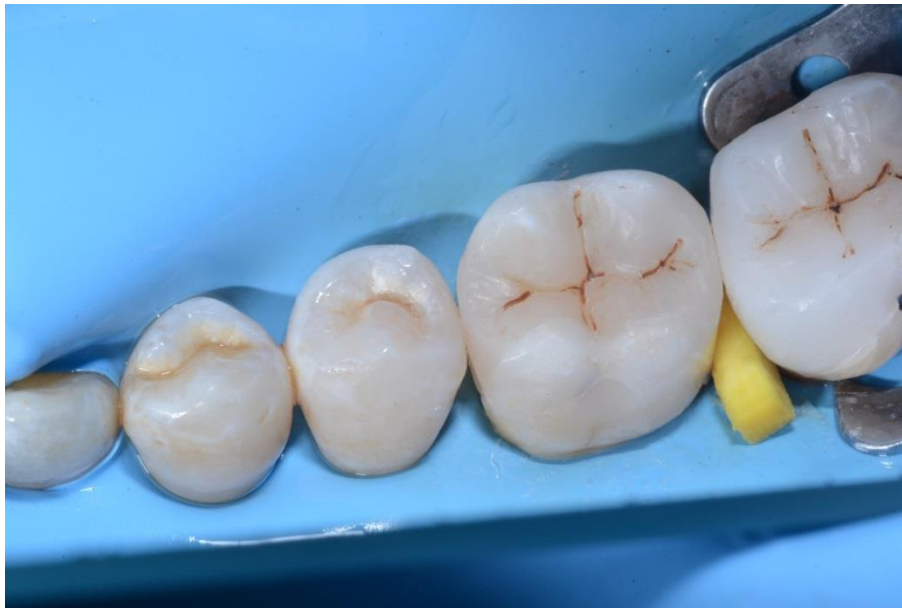07

Side view of # 46 after restoration of the distal and mesial interproximal walls.



08

The occlusal cavity filled with composite before finishing and polishing



09

Post-operative view of the restoration

Conclusion

The Polydentia myQuickmat Classico kit is a very effective system for posterior class II restorations.

The myQuickmat Classico kit offers an easy to use combination of a gentle separating ring and wooden wedge.

The Nickel Titanium myRing Classico, in combination with the new Delta Tubes allows to carefully form the matrix band around the tooth. The size and the shape of the Delta Tubes allows to adapt the matrix in a very efficient way without damaging and collapsing it on the cavity and thus ensuring an optimal restoration of the contact point. Teeth separation is performed efficiently by the combination of both myRing Classico and wooden wedges.